

The Zygomaticotemporal Branch of the Trigeminal Nerve: An Anatomical Study

Ali Totonchi, M.D., Nazly Pashmini, M.D., and Bahman Guyuron, M.D.

Cleveland, Ohio

This study was conducted to determine the site of emergence of the zygomaticotemporal branch of the trigeminal nerve from the temporalis muscle and to identify the number of its accessory branches and their locations. A pilot study, conducted on the same number of patients, concluded that the main zygomaticotemporal branch emerges from the deep temporal fascia at a point on average 17 mm lateral and 6 mm cephalad to the lateral palpebral commissure, commonly referred to as the lateral canthus. These measurements, however, were obtained after dissection of the temporal area, rendering the findings less reliable. The current study included 20 consecutive patients, 19 women and one man, between the ages of 26 and 85 years, with an average age of 47.6 years. Those who had a history of previous trauma or surgery in the temple area were excluded. Before the start of the endoscopic forehead procedure, the likely topographic site of the zygomaticotemporal branch was marked 17 mm lateral and 6 mm cephalad to the lateral orbital commissure on the basis of the information extrapolated from the pilot study. The surface mark was then transferred to the deeper layers using a 25-gauge needle stained with brilliant green. After endoscopic exposure of the marked site, the distance between the main branch of the trigeminal nerve or its accessory branches and the tattoo mark was measured in posterolateral and cephalocaudal directions. In ad-

dition, the number and locations of the accessory branches of the trigeminal nerve were recorded. On the left side, the average distance of the emergence site of the main zygomaticotemporal branch of the trigeminal nerve from the palpebral fissure was 16.8 mm (range, 12 to 31 mm) in the posterolateral direction and an average of 6.4 mm (range, 4 to 11 mm) in the cephalad direction. On the right side, the average measurements for the main branch were 17.1 mm (range, 15 to 21 mm) in the lateral direction and 6.65 mm (range, 5 to 11 mm) in the cephalic direction. Three types of accessory branches were found in relation to the main branch: (1) accessory branch cephalad, (2) accessory branch lateral, and (3) accessory branches in the immediate vicinity of the main branch. This anatomical information has proven colossally helpful in injection of botulinum toxin A in the temporalis muscle to eliminate the trigger sites in the parietotemporal region and surgical management of migraine headaches triggered from this zone. (*Plast. Reconstr. Surg.* 115: 273, 2005.)

Migraine headache affects approximately 18.2 percent of the female population and 6.5 percent of the male population in the United States alone.¹ One of every four households has a member who suffers from migraine headaches.¹ Recent clinical studies suggest that peripheral stimulation of the terminal branches of the trigeminal nerve by the surrounding

From the Division of Plastic Surgery, Case Western Reserve University, and the American Migraine Center. Received for publication September 16, 2003; revised January 15, 2004.

DOI: 10.1097/01.PRS.0000145639.42257.4F

muscles may cause central sensitization and trigger a migraine headache.^{2,3}

Studies conducted by the senior author of this article (Guyuron) have both retrospectively and prospectively demonstrated that removal of the glabellar muscle group (corrugator supercillii, depressor supercillii, and procerus) eliminates or reduces migraine headaches in properly selected patients.^{2,4} This study was conducted to determine the topographic site of the zygomaticotemporal branch of the trigeminal nerve as it exits from the deep temporal fascia, to facilitate both injection of botulinum toxin and identification of the nerve branches during the surgical procedures.

ANATOMY OF THE ZYGOMATICOTEMPORAL BRANCH OF THE TRIGEMINAL NERVE

The zygomaticotemporal nerve is a branch of the maxillary division of the trigeminal nerve. The maxillary division is the intermediate branch of the trigeminal nerve and is completely sensory in nature. It emerges from the trigeminal ganglion between the ophthalmic and mandibular nerves and extends anteriorly in a horizontal plane lateral and caudal to the cavernous sinus. It then traverses the foramen rotundum, crossing the upper part of the pterygopalatine fossa, inclines laterally on the posterior surface of the orbital process of the palatine bone, and then courses on the upper part of the posterior surface of the maxilla.

The zygomatic branch of this nerve originates in the pterygopalatine fossa, enters the orbit through the inferior orbital fissure, travels along its lateral wall, and bifurcates into zygomaticotemporal and zygomaticofacial branches (Fig. 1). The zygomaticotemporal nerve passes along the inferolateral angle of the orbit, provides a ramus to the lacrimal gland, traverses a bony canal in the zygomatic bone, and enters into the temporal fossa. This branch then ascends between the bone and the temporalis muscle (Fig. 2). It pierces the deep temporal fascia approximately 2 cm above the zygomatic arch to innervate the skin of the temporal area. It communicates with the facial and auriculotemporal nerves. As it pierces the temporal fascia, it sends a slender twig between the two fascial layers toward the lateral angle of the orbit. The lacrimal branch carries parasympathetic postganglionic fibers from the pterygopalatine ganglion to the lacrimal gland.⁵ A horizontal branch extends from this nerve to

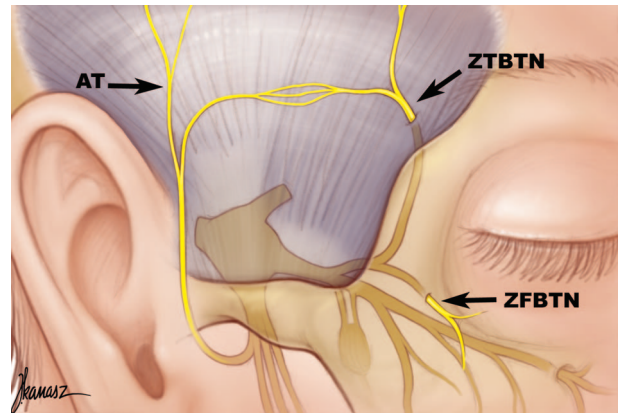


FIG. 1. Illustration of the zygomaticotemporal branch of the trigeminal nerve. AT, auriculotemporal; ZTBTN, zygomaticotemporal branch of the trigeminal nerve; ZFTBN, zygomaticofacial branch of the trigeminal nerve.

connect with the branches of the auriculotemporal nerve.

PATIENTS AND METHODS

Initially, 20 patients, 19 women and one man, who underwent endoscopic forehead surgery were included in the pilot portion of the study. After dissection of the temple region and exposure of the zygomaticotemporal branch of the trigeminal nerve, a 25-gauge needle was passed through the skin at a 90-degree angle to meet the nerve under observation through the endoscope. The distance of the needle from the lateral commissure was then measured in the horizontal (posterolateral) and vertical (cephalocaudal) dimensions. The actual distance of the main branch of the zygomaticotemporal nerve where it pierced the deep temporal fascia was measured and was on average 17 mm posterolateral and 6 mm cephalad to the lateral orbital commissure. However, this pilot study did not include identification of the accessory branches. Furthermore, because the measurements were obtained after dissection of the area, one could not rely sufficiently on the findings. To overcome this shortcoming, the methodology was altered during the main study.

In the main study, an additional 20 consecutive patients, 19 women and one man who underwent primary endoscopic forehead rejuvenation for the treatment of migraine headaches, were included. Patients who sustained previous trauma to this region or had undergone surgery in the forehead area were excluded from the study. Before starting the endoscopic forehead rejuvenation, the potential

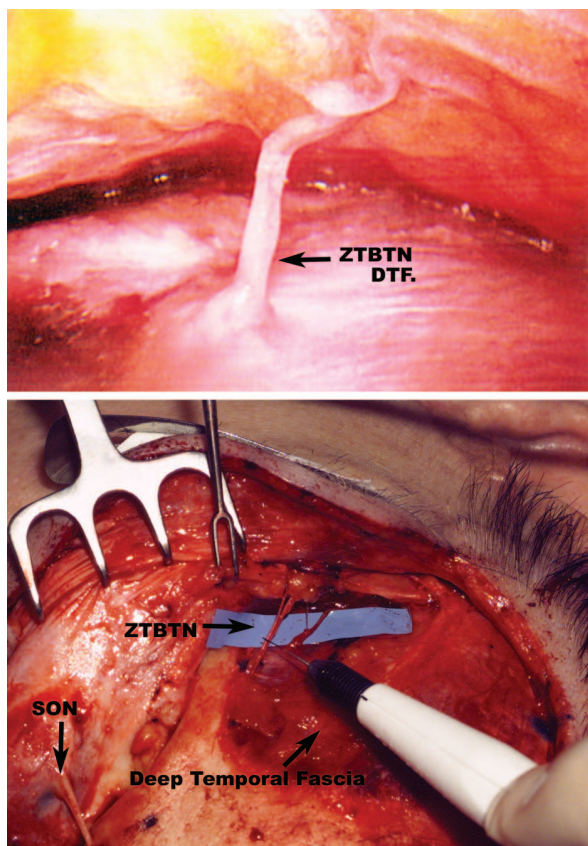


FIG. 2. Endoscopic (*above*) and open (*below*) views of the zygomaticotemporal nerve as it emerges from the temporalis muscle. ZTBTN, zygomaticotemporal branch of the trigeminal nerve; DTF, deep temporal fascia; SON, supraorbital nerve.

site of the zygomaticotemporal branch of the trigeminal nerve was marked on the basis of the pilot study. A point was selected exactly 17 mm posterolateral and 6 mm cephalad to the lateral orbital commissure. Using a 25-gauge needle stained with brilliant green solution, the skin marking was then transferred to the deep temporal fascia. Next, a routine endoscopic approach was used to expose the deep temporal fascia and dissect the temporal region, preserving the integrity of the zygomaticotemporal branches. Any variation of the nerve anatomy was identified and the distance of aberrant branches was measured from the tattoo point on the fascia in the horizontal (posterolateral) and sagittal planes. The results were then tabulated and analyzed.

RESULTS

The 20 patients in the main study ranged in age between 26 and 65 years, with the average age being 47.6 years old. A total of 65 measurements were recorded, 32 on the left side and 33

on the right. None of the patients in this consecutive series had to be excluded for the reasons of previous trauma or forehead surgery. Eight patients had only one main branch on each side. Twelve patients had at least one additional accessory branch on either side. Three patients had two accessory branches.

When the overall results were considered, the main zygomaticotemporal branch of the trigeminal nerve was on average 16.9 mm (range, 12 to 31 mm) posterolateral to the palpebral commissure and 6.5 mm (range, 4 to 11 mm) cephalad to the lateral palpebral commissure. On the left side, the average distance of the main zygomaticotemporal branch of the trigeminal nerve from the lateral orbital commissure, judged by the location of the tattoo mark, was 6.4 mm (range, 4 to 11 mm) in a cephalad direction. The distance from the lateral orbital commissure was 16.8 mm (range, 12 to 31 mm) in a posterolateral direction (Fig. 3). On the right side, the average measurement from the lateral orbital commissure was 6.65 mm (range, 5 to 11 mm) in a cephalad direction and 17.1 mm (range, 15 to 21 mm) in a posterolateral direction (Fig. 4).

The accessory nerves were found in three distinctive sites: superior to the main branch, posterolateral to the main branch, and immediately adjacent to the main branch (Table I). On the left side, the accessory nerve distribution was found in 10 patients:

TABLE I
Right-Side, Left-Side, and Bilateral Average Measurements and Number of Accessory Nerves

	Average Posterolateral (mm)	Average Cephalic (mm)	No. of Accessory Nerves
Left	16.8	6.4	12 in 10 patients
Right	17.1	6.65	13 in 11 patients
Bilateral	16.95	6.525	25 in 12 patients

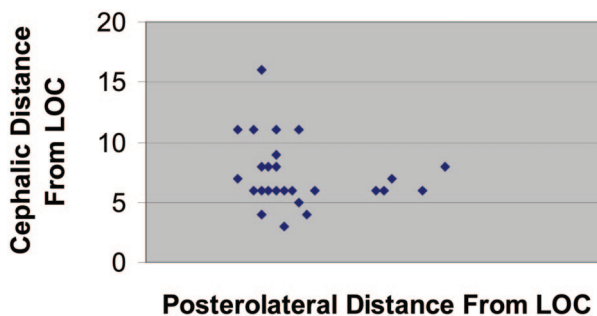


FIG. 3. The distribution of the left-side zygomaticotemporal nerve emergence point from the temporalis fascia.

- Accessory branches cephalad to the main branch were found in three cases, and one of the patients had two accessory branches in this area. These were located approximately 16 mm (range, 12 to 20 mm) posterolateral and 12.2 mm (range, 11 to 16 mm) cephalad to the lateral orbital commissure.
- Accessory branches lateral to the main branch area (on a line horizontally extending posterolateral from the main branch) were found in four cases. The average measurement was 34.2 mm (range, 30 to 39 mm) posterolateral and 6.7 mm (range, 6 to 8 mm) cephalad to the palpebral fissure.
- Accessory branches adjacent to the main branch were found in three cases, and one of the patients was noted to have two accessory branches in this area. The average measurement was 17.7 mm (range, 15 to 20 mm) lateral and 6 mm (range, 4 to 9 mm) cephalad to the palpebral fissure.

Accessory branches cephalad to the main branch on the right were found in six patients, and two patients had two accessory branches. The average measurements were 15.7 mm (range, 15 to 17 mm) posterolateral and 16.5 mm (range, 13 to 24 mm) cephalad to the palpebral fissure. Accessory branches posterolateral to the main branch were found in four patients. The average measurements were 28.7 mm (range, 26 to 33 mm) posterolateral to the palpebral commissure and 6.0 mm (range, 6 to 6 mm) cephalad to the orbital fissure. Accessory branches adjacent to the main branch were found in only one case on the right side, located 19 mm posterolateral and 5 mm cephalad to the orbital fissure.

The branches that were found posterolaterally were all directed horizontally to join the auriculotemporal branch of the mandibular division. The patients who did not have a sepa-

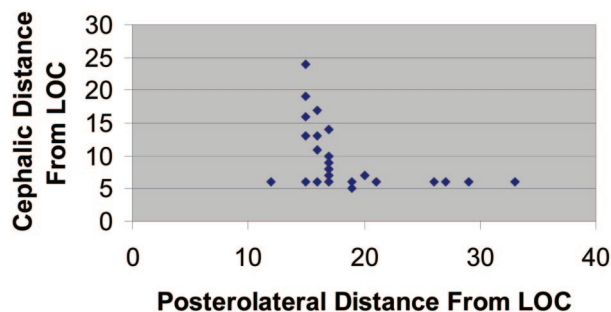


FIG. 4. The distribution of the right-side zygomaticotemporal nerve emergence point from the temporalis fascia.

rate branch piercing the deep temporal fascia all had the horizontal branch emerging from the main zygomaticotemporal branch of the trigeminal nerve above the fascia. This indicates a variation in branching of the zygomaticotemporal branch of the trigeminal nerve, whereby in some patients the horizontal branch arises from this nerve above the deep temporal fascia and in some patients below the fascia.

DISCUSSION

On the basis of our studies, the glabellar muscle group constitutes the most common trigger zone for migraine headaches, stimulating the supratrochlear and supraorbital branches. The second most likely trigger site of migraine headaches is located in the temporal region, where the zygomaticotemporal branch of the trigeminal nerve becomes irritated by being compressed by the temporalis muscle.⁶

Studies have shown that resection of the corrugator supercilii muscle and avulsion of the zygomaticotemporal nerve can lead to complete elimination of or significant improvement in migraine headaches.⁷ During surgery, an approximately 3-cm-long segment of the nerve is avulsed. This essentially removes the portion of the nerve that travels within or next to the muscle. The transected end retracts into the orbit. This study was conducted to identify the emergence point of the zygomaticotemporal branch of the trigeminal nerve from the deep temporal fascia to more easily locate the nerve during surgery and to provide a reliable topographic reference for injection of botulinum toxin A.

Using the *t* test for paired samples, we concluded that there was no statistical difference

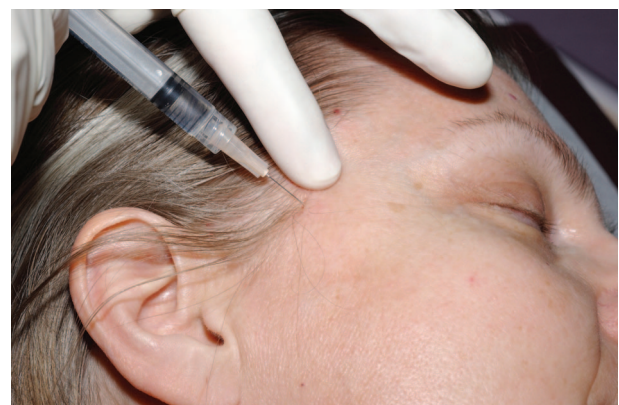

FIG. 5. Photograph demonstrating the method of botulinum toxin A injection in temporal area.

between the left-side and the right-side measurements. Because of an insufficient number of men (one of 20), it was not possible to investigate whether gender was a factor in the topography of the zygomaticotemporal branch of the trigeminal nerve or its accessory branching. Our predominantly female study population somewhat parallels the gender trend of migraine sufferers in the general public, with a female-to-male ratio of approximately 3:1. There is a dearth of literature describing the site of emergence of the zygomaticotemporal branch of the trigeminal nerve from the deep temporal fascia.

It is fascinating that a hollow area surrounds the point of emergence of the zygomaticotemporal branch of the trigeminal nerve and can be readily located by palpation. To inject this area, 12.5 to 25 units of botulinum toxin A is diluted in 0.5 cc of saline in a 3-cc syringe attached to a 30-gauge, 1-inch-long needle. With the left index finger (for a right-handed person) positioned in the nerve emergence site from the deep temporal fascia (Fig. 5), the needle is passed through the skin and the subcutaneous tissue, starting approximately 2 cm posterolateral to the left index finger and advanced through the deep temporal fascia. The location of this structure can be felt distinctly by a subtle increase in resistance as the needle passes through it, and botulinum toxin A is injected generously into this area and the deeper portion of the muscle. The needle can then be directed cephalad, posteriorly, and caudally, injecting the full extent of the muscle, if one finds it necessary on the basis of the clinical findings. The authors have noted a change in range of motion or strength of mandibular closure. However, the most important aspect of this injection is paralysis of the temporalis muscle fibers immediately adjacent to the zygomaticotemporal branch of the trigeminal nerve. In addition, the information

extrapolated from this study has been beneficial during surgery for the elimination of or improvement in migraine headaches in patients with refractory migraine headache. The surface marking properly guides the surgeon to the site of emergence of the zygomaticotemporal branch of the trigeminal nerve from the deep temporal fascia, thus simplifying the surgical procedure. Because injection of botulinum toxin A diffuses in a radius of 1½ cm, despite the variation in anatomy, it becomes efficacious by injection into the fascia penetration site. Further anatomical studies are in process to delineate the intramuscular branching of this nerve and the other nerves within the temporalis muscle.

*Bahman Guyuron, M.D.
29017 Cedar Road
Lyndhurst, Ohio 44124
bguyuron@aol.com*

REFERENCES

1. Lipton, R. B., Stewart, W. F., Diamond, S., et al. Prevalence and burden of migraine in the United States: Data from the American Migraine Study II. *Headache* 41: 646, 2001.
2. Guyuron, B. Corrugator supercilii muscle resection and relief of migraine headache: Findings of a retrospective study. *Today's Ther. Trends* 19: 59, 2001.
3. Burstein, R., Cutrer, M. F., and Yarnitsky, D. The development of cutaneous allodynia during a migraine attack: clinical evidence for the sequential recruitment of spinal and supraspinal nociceptive neurons in migraine. *Brain* 123: 1703, 2000.
4. Malick, A., and Burstein, R. Peripheral and central sensitization during migraine. *Funct. Neurol.* 15 (Suppl. 3): 28, 2000.
5. Williams, P. L., Warwick, R., Dyson, M., et al. *Gray's Anatomy*, 37th Ed. New York: Churchill Livingstone, 1989. Pp. 1098-1103.
6. Guyuron, B., Kriegler, J. S., Tucker, T., Davis, J., and Amini, S. Comprehensive treatment of migraine headaches. *Plast. Reconstr. Surg.* 115: 1, 2005.
7. Guyuron, B., Tucker, T., and Davis, J. Surgical treatment of migraine headaches. *Plast. Reconstr. Surg.* 109: 2183, 2002.